

# Marek's disease in vaccinated poultry flocks in and around Namakkal region of Tamil Nadu

A. Arulmozhi\*, S. Saravanan<sup>1</sup>, B. Mohan<sup>2</sup> and G.A. Balasubramaniam

Department of Veterinary Pathology

<sup>1,2</sup>Avian Disease Laboratory

Veterinary Hospital Campus, Namakkal - 637 002, Tamil Nadu

Received: 28.05.2011; Accepted: 17.06.2011

## ABSTRACT

Arulmozhi, A., Saravanan, S., Mohan, B. and Balasubramaniam, G.A. (2011). Marek's disease in vaccinated poultry flocks in and around Namakkal region of Tamil Nadu. *Indian J. Vet. Pathol.*, Vol 35 (1): 45-47.

The present study reports the mortality pattern, varying age susceptibility and altered gross pathology due to Marek's disease in white leghorn layers. A huge Marek's disease outbreak occurred even in vaccinated white leghorn layers farms in and around Namakkal district of Tamil Nadu resulted in severe economic loss to the poultry farmers and closure of small farms too. Epidemiological data were collected and the average flock mortality was about 10-40%. On clinical examination, the birds were weak, pale, off feed, poor performer, diarrhoeic, culls and showed nervous signs and blindness. Grossly, there was hepatomegaly, splenomegaly, hypertrophy of the proventriculus and tumour nodules in ovary and kidneys. Histopathologically, there was severe pleomorphic lymphocytic infiltration in liver, kidneys, ovary and nerves. As a consequence of the huge MD outbreak, the vaccine strategy was changed and now it is being practiced.

**Keywords:** Marek's disease, vaccination, white leghorn layer

## INTRODUCTION

Marek's disease virus (MDV) is a herpes virus, which cause lymphoproliferative disease in chickens. It is characterized by multiple T-cell lymphoma formation in visceral organs, skin, eye and lesion in peripheral nerves<sup>1</sup>. Even after the introduction of vaccines against MDV, the Marek's disease (MD) infection still causes considerable losses in poultry industry. A huge Marek's disease outbreak occurred in white leghorn layers in and around Namakkal district of Tamil Nadu which is the second largest poultry belt in India, resulted in severe economic losses to the farmers and subsequently led to closure of small farms. As a consequence of the huge MD outbreak, the vaccine strategy against MD was changed and now it is being practiced. The present paper describes the altered gross pathology and mortality pattern of Marek's disease which makes the diagnosis critical. A massive outbreak even in vaccinated flocks therefore deserved a place in the record.

## MATERIALS AND METHODS

Ailing birds and dead carcasses were brought by several farmers (more than 50 farms) from Jan'2006 to December'2006 to the Avian Disease Laboratory, Veterinary College Hospital Campus with the history of prolonged high mortality. The outbreak occurred on most of the farms with the capacity ranging from 10,000 to 2, 00,000 birds. Farm visits were also made for collection of epidemiological data regarding total

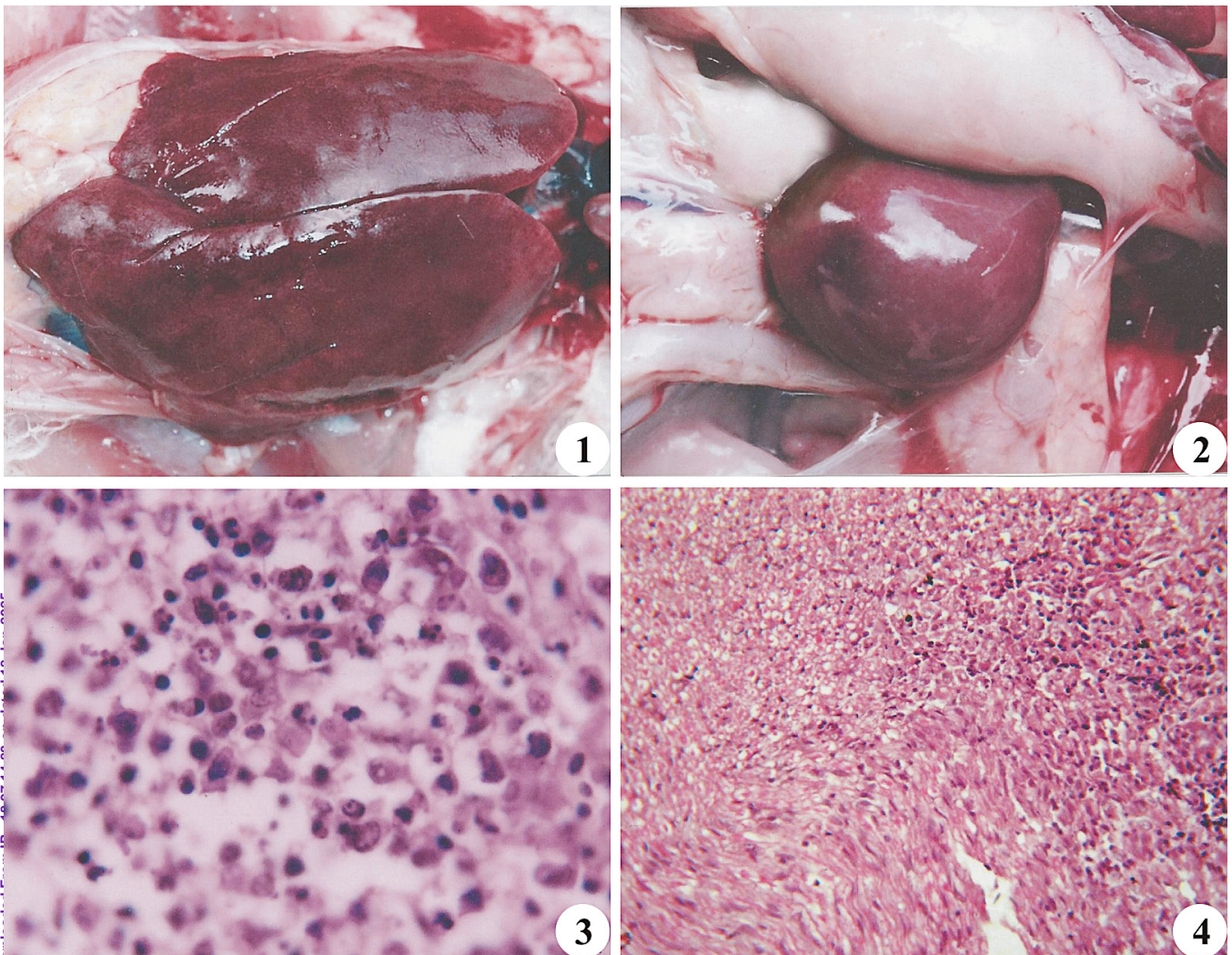
strength, number of affected birds, number of birds dead due to MD, clinical findings, vaccination status etc.

Post-mortem examination of carcasses were done to record the gross lesions and the tissue specimens were collected in 10% formol saline for histopathology. The feather follicles and other visceral organs were also collected and send to the Department of Animal Biotechnology, Madras Veterinary College, Chennai for Polymerase Chain Reaction (PCR) analysis.

## RESULTS

Epidemiological data represented the mortality that started at 16 weeks of age, peaked at 28-38 weeks of age and returned to normal by 50<sup>th</sup> week. But on few farms, lower mortality continued even up to 72 weeks with average flock mortality was about 10-40%. On clinical examination, the birds were weak, pale, off feed, poor performance, diarrhoea, culls and blindness. Only small no of birds in few farms exhibited the nervous signs. Grossly, grayish-white firm tumour nodules from pin-pint to 3 mm in diameter were seen on the liver parenchyma and some livers were abnormally enlarged and occupy the entire abdomen (Fig.1). Spleen was also obviously enlarged 3-5 times than that of normal size (Fig.2) and revealed miliary lymphomas scattered over the surface. Proventriculus was abnormally thickened and hypertrophied. Besides liver and spleen, tumourous growth was seen in gonads which appeared as cauliflower growth and kidneys were also abnormally enlarged. Histopathologically, liver sections revealed diffuse and massive accumulation of large lymphocytes

\*Corresponding author; e-mail: arulvinod2000@yahoo.co.in



**Fig.1.** Liver of MD affected birds showing severe enlargement and occupies the entire abdomen; **Fig. 2.** Splenomegaly in MD affected birds; **Fig. 3.** Liver section showing diffuse infiltration of pleomorphic lymphoid cells. H&E x1000; **Fig. 4.** Section of sciatic nerve of a MD bird showing diffuse infiltration of pleomorphic lymphocytes. H&E x100.

and lymphoblasts. The massive infiltration and proliferation of neoplastic lymphoid cells resulted in distortion of hepatic architecture, atrophy and replacement of the parenchymal tissue in the vicinity of these accumulations (Fig.3). In spleen, massive proliferation of small and large lymphocytes were observed in the splenic corpuscles. In kidneys, diffuse proliferation and infiltration of lymphoblastic cells was observed in the interstitial connective tissue, accompanied by partial to complete obliteration of renal tubules of cortex and medulla. The affected ovary showed massive infiltration and proliferation of pleomorphic lymphocytes, plasma cells and undifferentiated mononuclear cells which obliterated the normal parenchyma. Lesions in peripheral nerves consisted of extensive infiltration of mixed population of small and large lymphocytes resulted in complete obliteration of

normal architecture of the sciatic nerve (Fig.4). The PCR analysis of suspected samples confirmed the presence of MDV nucleic acid.

## DISCUSSION

The present epidemiological findings were in agreement with earlier reports where the higher mortality recorded in 21-40 weeks<sup>2</sup> and from 6 to 50 weeks<sup>3</sup>. However, our observations were not in agreement with the earlier reports where higher mortality in younger age groups from 9 to 20 weeks was reported. The gross observations in various organs were consistent and akin to earlier reports<sup>5</sup>. One important feature in this study noticed that, there was no gross enlargement of sciatic nerves or brachial plexus even in nervous sign exhibited birds which gave the complicate



picture for diagnosis. Birds suffering from acute MD without involvement of peripheral nerves also noticed by Fugimoto *et al.*,<sup>6</sup>. The histopathological changes in liver, spleen, kidneys, ovary, nerves etc. were similar to that observed by earlier workers<sup>7</sup>.

This massive and widespread outbreak in vaccinated poultry flocks might have occurred due to emergence of new virulent serotype of MDV in the Namakkal area of Tamil Nadu or failure of vaccination against the specific serotype. Before this outbreak, the vaccination was done with HVT at 0<sup>th</sup> day in hatchery. This massive outbreak calls for review of the vaccination strategy in the light of the reports of MD in the field in vaccinated flocks and thereby HVT+SB1 vaccination is now being practiced instead of HVT alone. Massive outbreak even in vaccinated flocks with altered gross pathology and disparity in age susceptibility therefore, deserved the recording and documentation.

#### REFERENCES

1. Calnek BW and Witter RL. 1991. Marek's Disease. In: *Diseases of Poultry*. Eds. Calnek BW, Barnes H.J, Beard CW, Reid WM, Yoder Jrs HW. 9<sup>th</sup> Edn. Iowa state University Press, Ames, Iowa, pp: 342-385.
2. Panda BK, Arya SC, Pradhan H.K and Johri DC. 1983. Marek's disease in chicken in various strains of White Leghorn. *Indian J. Poult. Sci.*, **18**: 100.
3. Balachandran C, Pazhanivel N, Vairamuthu S and Muralimanohar B. 2009. Marek's Disease and Lymphoid Leucosis in Chicken – A histopathological survey. *Tamilnadu J. Vet. Anim. Sci.*, **5** (4): 167-170.
4. Panneerselvam S, Dorairajan N, Balachandran C and Murali Manohar, B. 1990. Incidence of Marek's disease in Namakkal, Tamil Nadu. *Cheiron*, **19**: 143-144.
5. Narang G, Jindal N and Kumar S. 2003. Occurrence of Marek's disease in vaccinated layer flocks in Haryana. *Indian Vet. J.*, **80**: 590.
6. Fugimoto Y, Nakagawa N, Okada K, Okada M and Matsukawa K. 1971. Pathological studies of Marek's Disease and histopathology of field cases in Japan. *Jap. J. Vet. Res.*, **19**:7-26.
7. Kamaldeep, Sharma PC, Jindal N and Narang G. 2007. Occurrence of Marek's Disease in Vaccinated poultry flocks of Haryana (India). *International J. Poult. Sci.*, **6**(5): 372-377.

Calnek BW and Witter RL. 1991. Marek's Disease. In: *Diseases of Poultry*. Eds. Calnek BW, Barnes H.J, Beard CW, Reid WM,