

Abdominal Evisceration due to Dog bite and its Surgical correction in a Cat

D. Bhowmick¹, A. Shahi² and F. De Souza¹

Department of Surgery and Radiology
College of Veterinary Science and Animal Husbandry
Madhya Pradesh Pashu Chikitsa Vigyan Vishwavidyalaya
South Civil Lines
Jabalpur - 482001 (Madhya Pradesh)

ABSTRACT

A cat was presented with abdominal evisceration as a sequel of dog bite. On physical examination, the intestinal loops were found to be viable which was determined by its normal temperature, peristaltic movement, color and texture. The eviscerated mass was decontaminated with normal saline and antibiotic solution and then surgically replaced back into the peritoneal cavity. The cat was reported to have gone through an uneventful recovery.

KEYWORDS : Abdominal evisceration; cat; dog bite.

Introduction

Abdominal evisceration is defined as the herniation of the contents of the peritoneal cavity through the body wall with the exposure of the abdominal viscera (Cigdem *et al.*, 2006). Regardless of the inciting cause, exposure and contamination of the abdominal viscera, it warrants immediate surgical intervention (Smeak, 2003). The principles of pre-operative treatment include haemodynamic stabilization, antimicrobial treatment, extension of abdominal rent to prevent vascular compromise of eviscerated organs and application of surgical dressing until surgical intervention (Gower *et al.*, 2009). Most of the reported cases of evisceration occur post-operative, however in some instances they result from traumatic accidents or dog bites, such as in this case.

History and Diagnosis

A cat was brought with the history of a dog bite the previous night which resulted in abdominal evisceration. Physical examination revealed that the cat was off-feed and dull, with a normal rectal temperature and hydration status. The intestinal loops were viable, determined by normal temperature, peristaltic movement, colour and

texture (Fig.1). Anti-rabies post bite vaccine was administered.

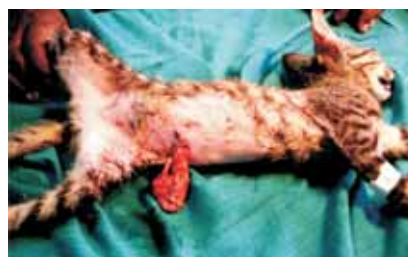

Fig. 1: Abdominal Evisceration

Treatment

To stabilize the cat, Inj. dextrose normal saline was administered i.v. @ 30 ml/kg followed by Inj. Moxel-D^a @ 25 mg/kg i.m., Inj. Isoflupredone @

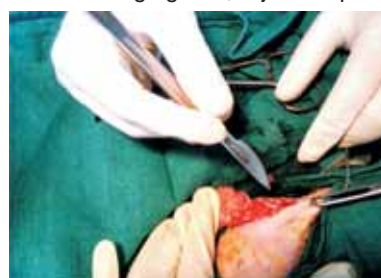


Fig. 2: Extending the abdominal rent

0.1 ml/kg i.m., Inj. Melonex^b @ 0.5 mg/kg i.m. The cat was anesthetized with Inj. diazepam @ 0.25 – 0.5 mg/kg i.v. and Inj. ketamine @ 15mg/kg i.v.. The eviscerated mass was decontaminated with

1 M.V.Sc. Scholar

2 Associate Professor

a - Brand of Alembic Ltd., Mumbai

b - Brand of Intas Animal Health, Ahmedabad

Abdominal Evisceration in Cat

normal saline solution and Inj. Moxel-D- 250 mg diluted with sterile water. The abdominal rent was extended to prevent vascular compromise of the intestinal loops and to permit smooth replacement (Fig.2)

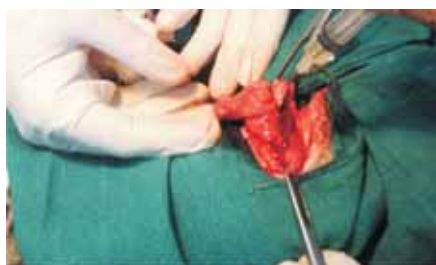

Fig. 3: Pouring the antibiotic solution over the eviscerated mass

The eviscerated mass was replaced into the peritoneal cavity after which it was lavaged with normal saline and Inj. Moxel-D-250 mg diluted with sterile water (Fig.3). The peritoneum and the muscular layers were apposed by simple continuous sutures and further strengthened with

simple interrupted sutures using chromic catgut No-0. subcutaneous sutures were applied followed by skin sutures with trusilk in interrupted fashion. Although the patient was a stray cat and left free after the operation, it went through an uneventful recovery.

Summary

Abdominal evisceration is not a common finding in cases of dog bites, even in cats. If treated immediately with certain points kept in mind such as shock, keeping the eviscerated organs moist, the animal has chances of survival post-operative.

References

- Cigdem, M.K., Onen, A. and Otcu, S. (2006). Post-operative abdominal evisceration in children: possible risk factors. *Pediatr. Surg. Int.* **22**:677-80.
- Gower, S.B., Weisse, C.W., Brown, D.C. (2009). Major abdominal evisceration injuries in dogs and cats: 12 cases (1998-2008). *J. Am. Vet. Med. Assoc.* **234**:1566-72.
- Smeak, D.D. (2003). Abdominal hernias. *In: Textbook of Small Animal Surgery*. 3rd Edn., Philadelphia: Elsevier Science. pp 449-69.

Intas Polivet Vol 12 Issue 1 Released

The last issue of Intas Polivet (Vol 12 Issue 1) was released during the 3rd International Case Management Competition, Clinical Case Conference and Symposium on 'Clinical Skill Development for the Next Generation Veterinary Practice' held at Madras Veterinary



College, Tamil Nadu Veterinary and Animal Sciences University (TANUVAS), Chennai on 14-15th July' 2011.

The issue was released by Dr R Prabakaran, Vice Chancellor, TANUVAS in presence of Dr P S Mohan Kumar, Veterinary Medical Centre, Michigan State University, US; Dr Elankumaran Subbiah, Center for Molecular Medicine and Infectious Diseases, Virginia Polytechnic Institute and State University, US; Dr V Sriranganathan, Virginia Maryland Regional College of Veterinary Medicine; Dr S Prathaban, Director of Clinics, TANUVAS and Dr S R Srinivasan, then Dean, Madras Veterinary College, TANUVAS during the valedictory function.

The occasion was graced with the presence of more than 250 budding veterinarians and eminent veterinarians of the country and abroad.