

Management of Punctured Wound in Greater One-Horned Rhinoceros (*Rhinoceros unicornis*)

N.S. Chaudhari¹, R.R. Nala², R.K. Singh³ and R.K. Patel⁴

Sardar Patel Zoological Park (SPZP)

Kevadiya - 393151 (Gujarat)

Abstract

A male greater one-horned rhinoceros suffered from right hind limb lameness due to wound on foot pad and between central and medial hooves along with severe inflammation of distal part of same limb. Based on history and clinical signs the case was diagnosed as puncture wound associated pododermatitis of right hind limb. Treatment was carried out using pressurized antiseptic solution, antibiotic, analgesic, tissue modifier drug and few altered husbandry practices. The condition completely healed after twenty days.

Keywords: Foot pad; lameness; pododermatitis; punctured wound; rhinoceros

Introduction

The greater one-horned rhinoceros, also known as the Indian rhino is classified as 'Vulnerable' wildlife species according to the IUCN red list. In the wild, approximately 3624 greater one-horned rhinoceros are estimated to be wandering in India and Nepal (Kakati *et al.*, 2020). While, forty-six Greater one-horned rhinoceros were housed in Indian zoos (WII, 2016).

In general, greater one-horned rhinoceros in captivity remain healthy and long-living as stated by Jones (1979), but few cases of injuries and other diseases like gastric ulcer and impaction have also been described by other authors (Singh *et al.*, 2015). Miller and Buss (2015) described that various types of injuries are common among both captive and free-ranging rhinoceros. Mainly injuries are caused by acute or chronic rubbing, damage from the enclosure and sometimes intraspecific fighting especially during mating while courtship chases in wild, which may result in scrapes, cuts or deeper wounds (Bajaj *et al.*, 2021).

In a decade long study among Indian zoos it was found that rhinoceros (358 cases) suffered mainly due to wound and infighting injury, anorexia, diarrhoea, conjunctivitis, debility, stress, nephritis, GIT infection, tympany, endoparasitic infection, rectal prolapse, lameness, sprain, abscess, dermatitis and Johne's disease. Post-mortem findings revealed cardio-respiratory failure, pneumonia, dehydration,

pyaemia, stillbirth, cardiac tumor, toxemia, peritonitis and senility as the causes of death (Swarup *et al.*, 2009). A case of fistulae and ulcers in feet of captive Indian rhinos was described by Houwald (2001), for which treatment was difficult and unrewarding. However, the principle of treatment of such injuries involves debridement, antibiotics, wound dressing, probiotics and fly control. The present case describes the treatment of a punctured wound associated with pododermatitis on right hind limb of greater one horned rhinoceros.

History

A fourteen years old zoo born male Greater one horned rhinoceros was showing hind limb lameness for a week. Clinical examination revealed wound on the footpad and between central and medial hooves of right hind limb along with severe inflammation of distal part of same limb (Fig. 1 and 2). The interdigital wound was showing frothy secretion along with purulent exudates. A pus swab sample was taken for cultural isolation and antibiotic sensitivity test. Based on history and clinical signs, the case was diagnosed as punctured wound associated with pododermatitis of right hind limb.

Gross Anatomy of Rhino's feet

Rhinos have short legs to carry a massive and robust body. The forelegs of rhinos appear broad and round as compared to hind legs which are relatively elongated in appearance. The hind feet are generally larger than front feet. The digits are arranged in semi-circular fashion around the pad. The hooves generally touch the ground while in a standing position. Rhinos have three digits that are: second, third and fourth with a large expanding digital cushion. There are six tarsals, three metatarsals and three digits bearing three phalanges each (Sinha *et al.*, in press).

1. Veterinary Officer and Corresponding author.
E-mail: niteshchaudhari95@gmail.com
2. Director
3. Veterinary Officer, In-Charge, Canine Rabies Control Unit, Meerut, Uttar Pradesh
4. Biologist

Wound management in rhinoceros

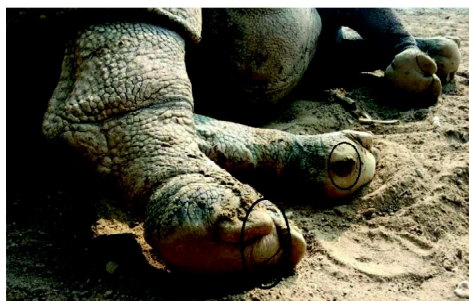

Fig. 1: Circle showing foot pad wounds

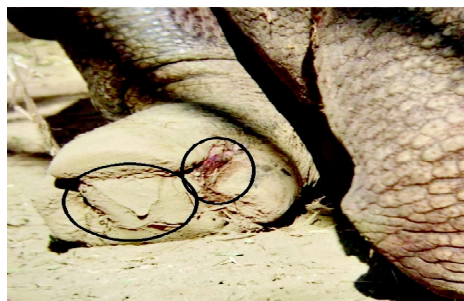


Fig. 2: Circle showing punctured wound between central and medial hooves of right hind limb



Fig. 3: Foot bath filled with antiseptic solution for wound cleaning



Fig. 4: Circle showing completed healed wound

Treatment

Proper dressing of punctured wound was not possible without sedation, which is not possible during every dressing process. And due to large size and heavy weight of animal, sedation is not advisable on regular basis for wound treatment because an anesthetic drug could cause injuries, tympany and other recumbency related complications. Therefore, a pressurized foot pump method was used for cleaning and debridement of wound with 2 percent Potassium permanganate and 1 percent Povidone-iodine solutions followed by application of antiseptic Povidone-iodine/antibacterial wound dressing powder and wound healing spray through comfortable distance. The animal was also given injection Amikacin (Venkacin^a) at 10 mg/kg b.wt. intramuscularly in the dorsal part of neck region by dart gun for five days, Bolus Meloxicam (Melonex^b) at 0.5 mg/kg b.wt. orally and bolus containing Isoflupredone 10 mg and

a - Brand of Venkys India, Pune

b - Brand of Intas Animal Health, Ahmedabad

c - Brand of Genetico Drugs, Haridwar

d - Brand of Provimi Ltd, Bengaluru

Serratiopeptidase 60 mg (Gendone-S 60^c) eight boluses in three divided doses orally in bananas for a week. For good tissue recovery supportive therapy with syrup Vitamin E and Selenium (E-care Se^d) at 50 ml and probiotic powder 50 gm by oral route as tissue modifier on an alternate day basis was given until the condition was improved. Apart from this, to treat repeated soil-born infection, the night house of rhino was provisioned with foot bath of full width of house containing povidone-iodine, potassium permanganate and fly repellent solution (Fig. 3). The rhino was encouraged to use a foot bath most of the time in a day by repeatedly offering fruits one by one to him. A mixture of turmeric powder and antibiotic was regularly sprinkled in the walking place of rhino to check infection.

Results and Discussion

According to Atkinson *et al.* (2001), chronic pododermatitis is a poorly understood but common medical condition, which affects up to 28 percent of adult male Rhinos in captivity. It generally affects the hind feet and is characterized by non-healing fissures and ulcers located between the sole of central toe and adjacent pad and by pad overgrowth,

bruising and chronic infection. Potential contributing factors include massive body size and weight, inappropriate housing conditions and husbandry techniques and genetic predisposition. The management plan for this animal includes improvements in husbandry techniques, medical and surgical therapy. In our case, also hind foot was affected and lesion was almost same. The animal was treated with several suitable medicines, remote wound cleaning method and altered husbandry techniques by providing a foot bath of Potassium permanganate.

Atkinson *et al.* (2002) described debridement, antibacterial ointment, cleaning with an antiseptic solution for management of abscess and footpad ulcer in Greater one-horned rhinoceros. In our case, also wound was managed similarly.

Gram-positive cocci were found in pus swab sample collected from wound on cultural isolation. However, bacteria couldn't be isolated on cultural examination. Antibiotic sensitivity test revealed microorganisms were sensitive to Amikacin, Gentamicin and resistant to Penicillin, Tetracycline, Ampicillin and Enrofloxacin. In this case, Amikacin injection along with supportive treatment such as tissue modifier and analgesic drugs resulted in the recovery of the animal. The pyogenic layer of a punctured wound in such a large animal like rhinoceros remains a great challenge for the zoo Veterinarian to treat and it's not possible to give sedation to animal daily for treatment of such wounds. Therefore, a pressurized foot pump for cleaning and debridement of punctured wounds to prevent further microbial growth was used. Singh *et al.* (2014) also used the same mechanism for debridement and cleaning of wound and application of an antiseptic solution.

Conclusion

The condition was completely healed after twenty days (Fig. 4). The method for treating rhinoceros used in Sardar Patel Zoological Park, Kevadiya is very simple, economical and may be used in such type of conditions among other mega herbivore animals like Elephant, Bison, Giraffe and Hippopotamus. In conclusion, in zoos that are facing difficulty in treating such conditions in large animals, this kind of simple method for treating wounds will certainly prove helpful to save endangered animals.

References

- Atkinson, M.W., Hull, B., Rae, G.A. and Blumer, E.S. (2001). Long-term medical and surgical management of chronic pododermatitis in a Greater one-horned rhinoceros (*Rhinoceros unicornis*): A Progress Report, *Scientific Progress Reports - Vienna* 159-63.
- Atkinson, M., Hermes, R., Rookmaaker, K., Rosemary, D., Trupkiewicz, J. G. and Walzer, C. (2002). Husbandry manual for the Greater one-horned or Indian rhinoceros *Unicornis* Linné. *Basel Zoo*. 42.
- Bajaj, A., Singh, R.K., Srivastava U.C., Nasir, M. and Sultana F. (2021). A Study on mating behaviour of Great Indian one-horned rhinoceros in captivity. *Ind. Zoo Yearb, CZA, New Delhi*. 9: 74-78.
- Houwald, V. and Frein, F. (2001). Foot problems in Indian rhinoceroses (*Rhinoceros unicornis*) in zoological gardens: macroscopic and microscopic anatomy, pathology and evaluation of the causes. *University of Zurich, Vetsuisse faculty, Zurich*. 72.
- Jones, D.M. (1979). The husbandry and veterinary care of captive Rhinoceroses. *Int Zoo Yearb* 19: 239-50.
- Kakati, P.K., Islam, I., Sharma, A. and Ghosh, T. (2020). Prevalence of endoparasitic infections in free-ranging Greater one-horned rhinoceros in Jaldapara National Park and Gorumara National Park, West Bengal - A technical report. *World Wide Fund for Nature-India*. New Delhi. 11.
- Miller, M.A. and Buss, P.E. (2015). Rhinocerotidae. In: Miller R.E. and Fowler M.E. (eds.). *Fowler's Zoo and Wild Animal Medicine.*, (8th Edn.), Saunders, Missouri. 544.
- Singh, R.K., Srivastava U.C. and Nasir, M. (2015). Management of impaction in Greater one-horned rhino. *Zoos' Print J*. 30: 15-17.
- Singh, R.K., Srivastava U.C. and Nasir, M. (2014). Brief description of wound management in One-horned rhinoceros in captivity. *Ind. Zoo Yearb, CZA, New Delhi*. 7: 123-26.
- Sinha, R., Prabhakar and Singh, A. (In press). Gross morphometrical studies on bones of hind limb of calf Great Indian rhinoceros (*Rhinoceros unicornis*). Section of Veterinary Anatomy, College of Veterinary Science, SVPUAT, Meerut (UP), India.
- Swarup, D., Das, A., Saini, M., Pankaj, K., Sharma, A.K. and Pal, A. (2009). Standards, guidelines and protocol on disease diagnosis and cure of wild animals in Indian zoos. Indian Veterinary Research Institute, Izatnagar and Central Zoo Authority, New Delhi. 20.
- Wildlife Institute of India (2016). *National Studbook of One-horned rhinoceros*. (3rd edn.). Wildlife Institute of India, Dehradun and Central Zoo Authority, New Delhi.

Received on: 06.02.2022
Accepted on: 19.04.2022