

## Canine Tusk Trimming under Detomidine Sedation in a Hippopotamus (*Hippopotamus amphibius*)

B. Justin William<sup>1</sup>, L. Nagarajan, C. Ramani, S. Jeyakumar, T. Peter Nolosco, G.D. Rao, H. Pushkin Raj and R. Sureshkumar

Department of Veterinary Surgery and Radiology  
Madras Veterinary College  
TANVASU, Chennai – 600 007 (Tamil Nadu)

### Abstract

An adult male Nile Hippo aged 14 years and weighing about 3000 kilograms was administered with 20 µg/kg of detomidine for trimming of its overgrown canine tusks at the lower arcade. Detomidine provided standing sedation for 42 minutes enabling oral examination and trimming of the tusk.

**Key Words :** Hippopotamus, tusk trimming, detomidine, standing sedation

### Introduction

The family hippopotamidae contains two genera, the Nile River Hippopotamus (*Hippopotamus amphibius*) and Pygmy Hippopotamus (*Choeropsis liberiensis*). Nile River Hippopotamus males weigh between 1300–3200 kilograms and females between 655–2344 kilograms. Though Nile Hippos seem to be quiet and fascinating animals in circus and zoos; they are the most dangerous animals, highly ferocious when agitated, killing more people than crocodiles and no animal predators are available to predate them. Hippos yawn with jaws at 150° incredibly either to beg food in captivity or when angry showing their big teeth to bite or charge (Boitani and Bartoli, 1982 and Taylor and Greenwood, 1986). The simple low crowned molars are used for chewing, incisors for digging and tusk like canines for fighting. In male hippopotamus canine teeth of the lower arcades weigh around 4 kg and grows up to 1.50 feet and are usually four times the weight and twice the length of the canines in females. They are kept sharpened by constant vertical wear against the shorter upper canines. Chemical restraint and anaesthesia of the hippopotamus pose significant difficulties to veterinary anaesthetists due to the temperament,

large size, amphibious habit, thick skin, aggressive demeanor (Flach *et al.*, 1998) and ventilation–perfusion mismatch leading to hypoxemia (Hornof *et al.*, 1986). This paper describes a case report on chemical restraining a Nile River Hippopotamus for canine tusks trimming under detomidine, an alpha 2 adrenergic agonist.

### Case History

An adult male Nile Hippopotamus aged 14 years and weighing about 3000 kg was referred to the Madras Veterinary College, Chennai from a private circus for overgrown canines on both the lower arcades. The hippo was not able to close the mouth and painful ulcers were noticed on the gums of upper arcades (Fig. 1). The animal was fed with rice gruel since one year. Hence, it was decided to trim the overgrown canines.

### Treatment and Discussion

The hippo was starved for 24 hours and the procedure was started at 6.00 a.m. The animal was removed from the tank and access to water was blocked. Detomidine was administered at the dose of 20 µg/kg intramuscularly using a spinal needle at the left lateral aspect of the anus. The skin was kept moistened by covering with blankets soaked in cold water. The water level in the tank was kept at 15 cms level to avoid untoward incidence in case of reentry to the tank.

The onset of sedation was noticed in 2.45 minutes and duration of sedation lasted for 42 minutes. Sedation was characterized by drooping of head, resting the lower jaw and lips on the ground and buckling of hind limbs and the animal was in standing position throughout the period of sedation. Detomidine at the dose of 20 µg/kg b.wt. induced and maintained sedation sufficient for buccal examination and tusk trimming in standing position in the present study. Clyde *et al.* (1998)

Corresponding Author: Professor

### Tusk Trimming in Hippopotamus

immobilised a female hippo with 0.026 mg/kg of detomidine and 0.04 mg/kg of butorphanol for dermatological evaluation. The result was 65 minutes of recumbency with incomplete sedation and the animal was accessed through a sturdy chute. Morris *et al.* (2001) used a combination of

and Ramsay, 1999 and Morris *et al.*, 2001). Detomidine at the dose rate of 20 µg/kg provided standing sedation without untoward incidences associated with ventilation-perfusion mismatch leading to hypoxia and hypercapnea (Hornof *et al.*, 1986).

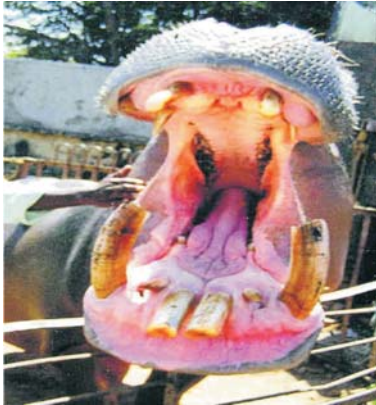

Fig. 1 : Overgrown canine tusks-unable to close the mouth



Fig. 2 : Trimming of right overgrown canine tusk with foetotomy wire

0.055 mg/kg of detomidine and 0.15 mg/kg of butorphanol tartrate in young hippos suitable to conduct physical exams, phlebotomy and other routine procedures. The common chemical restraint agent used in hippos were etorphine (1-5 µg/kg) with or without xylazine (67-83 µg/kg) or acepromazine as a component with etorphine mainly for tusk trims (Pearce *et al.*, 1985, Loomis

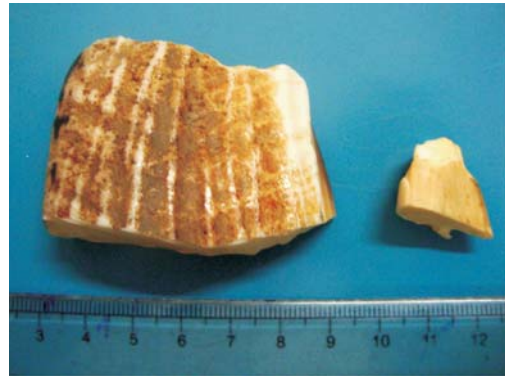


Fig. 3 : Trimmed portion of right lower and upper overgrown canine tusk

The length of the right and left lower canine tusks were one foot and four inches and one foot and six inches respectively. The gums and lips were protected and the over grown tusks were trimmed 1/3<sup>rd</sup> leaving 2/3<sup>rd</sup> using a foetotomy wire (Fig. 2 and 3) and the animal was able to chew apple immediately after recovery.

The skin of hippopotamus is thick and the ectodermal thickness is more than six centimeters hence the site of injection selected was lateral to the anus below the tail fold as the thickness is minimal in this area and this site was recommended for the administration of emergency drugs. Intramuscular injection did not evince pain as the hippo's skin is insensitive. Hippopotamus does not possess sweat gland and when out of the water for a while their skin oozes a thick, pinkish, oily liquid called "blood sweat" from the mucous gland to protect the skin from sun burn and infection and this secretion increased during sedation could be due to the stress associated with chemical restraint.

Detomidine at the dose of 20 µg/kg produced safe and reliable standing sedation sufficient for buccal

William *et al.*

examination and canine tusk trimming in Nile hippopotamus.

### Summary

Successful bilateral canine tusk trimming was performed in an adult male Nile Hippopotamus (*Hippopotamus amphibius*) aged 14 years and weighing about 3000 kg under detomidine at the dose of 20 µg/kg l/m in standing restraint.

### References

- Boitani, L. and Bartoli, S. (1982). Hippopotamus and Pygmy Hippopotamus. In : *Simon and Schuster's Guide to Mammals*. Anderson, S. (ed), Simon and Schuster Co. New York. pp. 354-55.
- Clyde, V.L., Wallace, R.S. and Pocknell, A.M. (1998). Dermatitis caused by group G.beta-hemolytic *Streptococcus* in Nile hippos. In Proceedings of the *Am. Assoc. Zoo. Vet.* p.221.
- Flach, E.J., Furrokh, I.K. and Thornton, S.M. (1998). Caesarean section in a pygmy hippopotamus (*Choreopsis liberiensis*) and the management of the wound. *Vet. Rec.* **143**: 611-13.
- Hornof, W.J., Dunlop, C.L., Prestage, R. and Amis, T.C. (1986). Effects of lateral recumbency on regional lung function in anaesthetized horses. *Am. J. Vet. Res.* **47**: 277-82.
- Loomis, M.C. and Ramsay, E.C. (1999). Anesthesia for Captive Nile Hippopotamus. In : *Zoo and Wild Animal Medicine: Current therapy* WB. Saunders Co., Philadelphia. pp. 638-39.
- Morris, P.J., Bicknese, B., Janssen, D., Loudis, B., Shima, A., Sutherland – Smith, M. and Young, L. (2001). Chemical restraint of Juvenile East African River Hippopotamus at the San Diego Zoo. In : *Zoological Restraint and Anesthesia*. Heard, D. (ed) International Veterinary Information Service, New York.
- Pearce, P.C., Knight, J. and Gustavo, C. (1985). Immobilisation of a pygmy hippopotamus (*Choeropsis liberiensis*). *J. Zoo Anim. Med.* **16** : 104.
- Taylor, G. and Greenwood, A. (1986). Hippopotamidae. In : *Zoo and Wild Animal Medicine*. Fowler, M.E. and Miller (eds) WB. Saunders Co. Philadelphia pp. 967-969.



### 4<sup>th</sup> Indian International Pet and garden Trade Fair (IIPTF) hosted in Delhi

The NSIC Exhibition Centre, Okhla Industrial Area, New Delhi hosted the 4<sup>th</sup> IIPTF on 12<sup>th</sup> -14<sup>th</sup> February' 2010 with more than 150 exhibit stalls and galaxy of pet lovers from India and abroad. According to Euromonitor International there are currently 8,699,300 pets in India with an annual growth of 26% each year. Indian sub-continent has presently a large human population of 1.15 billion people and their inclination towards companion animal was evident in the trade fair.