

CASE REPORT

A difficult case of obstructive sleep apnea with obesity hypoventilation syndrome

D. Bhattacharya, S. Chakrabarti, M. K. Sen, J. C. Suri

See end of article for authors affiliations

Indian J Sleep Med 2006;1.1, 58-64

Abstract: A middle aged morbidly obese lady with symptoms of obstructive sleep apnea and obesity hypoventilation syndrome was admitted to our hospital emergency in circulatory and Type II respiratory failure. She was resuscitated and put on invasive mechanical ventilation. After extubation she was put on non invasive bilevel positive airway pressure ventilation. Despite two weeks on ventilatory support the patients blood gas did not show significant improvement. The patient was given a trial of oral medroxyprogesterone and aetazolamide with continuation of BiPAP support. By two weeks the patient could be discharged on nocturnal non invasive BiPAP ventilation

Address for correspondence an reprint request:

Dr. J. C. Suri, Head of the Department of Pulmonary, Critical Care & Sleep Medicine, Room No. 404, Casualty Block. Safdarjang Hospital, New Delhi, India – 110023

Introduction

Obesity hypoventilation syndrome is characterized by the coexistence of obesity (body mass index > 30 Kg/m²) and hypercapnic respiratory failure (PaCO₂ > 45 mmHg) in the absence of other known cases of hypoventilation.

OHS was originally described in 1955 in subjects with obesity, chronic day time hypercapnia and hypoxemia, polycythemia, hyper somnolence and right heart failure (1). There are factors other than obesity which lead to the development of hypoventilation, since only a minority of obese patients have hypoventilation (2,3). A defect in the central respiratory controller appears to be most important in causing the observed hypoventilation with observations of decreased ventilatory response to CO₂ rebreathing (4). In addition there are reports of patients with normal response to CO₂ but attenuated ventilatory response to hypoxia (5). In this report we present one such case where short term use of respiratory stimulants helped reset the respiratory central control in a patient of OSA with OHS who could then be managed on nocturnal bilevel non invasive ventilation alone.

Case report

The patient a middle aged morbidly obese lady with a history of snoring for 18-20 yrs and nocturia for 10-12 yrs presented to our hospital emergency department in June 2004 with complaints of excessive day time sleepiness for the past two years, which was particularly worse for the past one month. The patient had been gaining weight progressively over the past 10-12 years and at the time of admission she tipped the scales at 144 Kg. She had on a number of occasions dropped objects in the kitchen or elsewhere in the course of her daily chores. The patient had noticed a progressive increase in breathlessness since the past 6 months, which was particularly worse for the last one month. In the past month patient had also noted some jerky movements of her upper limbs for which she sought a neurological opinion. The neurologist suspected a sleep disordered breathing and advised her to seek a respiratory consultation. There was no history of cough or

Abbreviations: OSA: obstructive sleep apnoea; OHS:obesity hypoventilation syndrome; BiPAP: bilevel positive airway pressure; NIV: non invasive ventilation; PIP: peak inspiratory pressure; PP: pause pressure; MPA: medroxyprogesterone acetate; ACET: acetazolamide

expectoration, chest pain, haemoptysis, palpitations or fever. The condition of the patient had within the past one month deteriorated progressively and when admitted she had been off her replacement thyroid medication for three weeks and without food or liquids for the last 24-36 hours.

The patient was a known case of bronchial asthma since 1980 for which she had been on intermittent oral bronchodilators and steroids. She had never been on inhalation therapy neither had she ever been admitted for exacerbation of bronchial asthma. She had been diagnosed hypertensive for five years and had since been on regular medication. She was also found to be hypothyroid since three years and was on replacement therapy.

The patient had a family history of hypertension, diabetes and ischemic heart disease.

On examination the patient was a middle aged grossly obese lady. She was drowsy but oriented in time and space. She was afebrile. Her skin was dry, had puffiness on her face with bilateral pitting edema of the feet. There was no pallor, lymphadenopathy, clubbing, cyanosis or icterus. Her resting pulse was 60/min, regular; her respiratory rate was 54/min and blood pressure 90 mm Hg systolic. Her extremities were cold and oxygen saturation by finger probe was 62% (lying down). The patient's neck circumference was 44 cm and corrected neck circumference 51 cm (correction factor + 4 cm for hypertension and + 3 cm for snoring) (6). The patient's weight on admission was 144 Kg with a height of 161 cm (BMI – 53 Kg/Ht²).

Examination of the chest revealed bilateral expiratory wheeze & basal crackles. Examination of the cardiovascular and central nervous systems were

essentially normal. The abdomen was distended with a palpable liver, 2cm BCM. The spleen was not palpable and there was no shifting dullness.

Her investigations were essentially normal, except for elevated TSH levels. Her X-ray Chest was normal. ECG showed evidence of p pulmonale. Her ABG on admission showed ; PaO₂ = 36.25, PaCO₂ = 70.6, PH = 7.32 & HCO₃ = 35.3.

The patient was transferred to the ICU and given low flow oxygen at 3 LPM. Her PaCO₂ increased from 70.6 to 80.6 mmHg and the patient became more drowsy. Patient was electively intubated because of Type II respiratory failure and impending respiratory arrest.

During intubation the airways had minimal secretions. The patient was put on mechanical ventilation – assist control mode with the settings of TV = 360 ml, RR = 20/min, FiO₂ = 100%. On these settings the peak airway pressure was 31-32 cm and pause pressure was 20-21 cm. The patient was resuscitated with fluids and inhaled bronchodilators given. Following these measures over the next two hours the patient's blood pressure increased to 110 mm hg systolic, her peripheries became warm and PIP fell to 25-26 cm & PP fell to 18 cm. The patient remained on mechanical ventilation between 12.06.2004 to 22.06.04. Despite ventilatory support the patient's PaCO₂ remained above normal. (Table 1) Also, extubation of the patient had to be delayed as the patient continued to require a high FiO₂ (40%), which would be difficult to attain on NIV support. Patient was extubated on 22.06.2005 and put on non invasive BiPAP ventilation on a pressure of 16/8. However as noted from the ABG chart (Table 2) her partial pressures of oxygen did not show an improvement, neither did the PaCO₂ fall over the next few days of BiPAP ventilation.

Table 1: ABG's of the patient on ventilator

Dated	12.06		Intubation	13.06	14.06	16.06	17.06	18.06	21.06	22.06
FiO ₂	20.9	3½ LPM	100%	60%	45%	35%	45%	35%	45%	40%
PaO ₂	36.2	49.2	198.4	65.9	65.3	58.2	58.0	58.2	75.3	66.8
PaCO ₂	70.6	89.8	57.6	53.0	48.2	63.2	52.5	63.2	46.5	54.1
PH	7.32	7.276	7.370	7.387	7.441	7.415	7.459	7.415	7.454	7.48
HCO _{3a}	35.2	39.2	32.3	30.9	32.1	39.2	34.3	39.2	31.6	38.6
A-a DO ₂			430.0							
						PS + PEEP 16/6	PS + PEEP1 2/6		PS + PEEP 10/6	Extubated

Table 2: ABG's on NIV (post extubation)

Dated	23.06	23.06	25.06
FiO ₂	20.9	40% (V)	20.9
PaO ₂	40.7	67.1	49.3
PaCO ₂	53.3	53.8	54.5
PH	7.440	7.384	7.407
HCO _{3a}	35.1	31.3	33.2

The patient was investigated further. Her PFT suggested a moderate obstructive ventilatory defect (FEV₁/FVC – 69% of predicted) with a decreased FVC (54% of predicted). An ENT examination revealed a retrognathic profile with nuchal obesity. The oral cavity was small with grade III tongue. The palates were thick and short, the uvula <10mm with grade II lateral pharyngeal bands. The tonsillar bulk was grade I and the nose showed changes of chronic hypertrophy. An ECHO done showed a dilatation of RA & RV with RVSP of 46 mmHg with an EF of 55-60%. In view of the refractory PaO₂ and persistently raised PaCO₂ a derangement of respiratory centre control was suspected and the patient was started on medical therapy (medroxy progesterone acetate 20 mg TDS & acetazolamide 250 mg twice daily) to augment respiratory centre drive from 20.06.2004. The patient who had a refractory hypoxemia with further fall in O₂ saturation in the supine posture showed a marked improvement over the next two weeks. The patient's awake SPO₂ improved to 93-94% and SPO₂ on lying down which was 62% at admission improved to 82-83% and on BiPAP support improved to 90%. The patient's ABG on room air in awake state also showed a remarkable recovery (Table –3). The IPAP pressure of BiPAP could not be increased more than 19 cm because of mouth leak.

The patient underwent a split night polysomnography on 06.07.2005 (Fig 1 to 4). The PSG showed a saturation of 86% on awake state. As the patient slipped into stage II sleep her PSG showed multiple episodes of apneas,

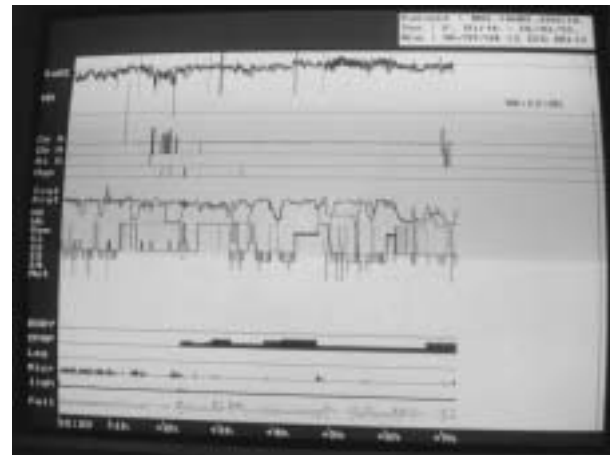Table3: ABG's of patients after starting MPA and ACET

Dated	26.06	30.06	01.07	05.07	11.07
FiO ₂	20.9	20.9	20.9	20.9	20.9
PaO ₂	50.3	54.9	63.2	63.0	63.1
PaCO ₂	54.1	50.9	48.5	45.8	37.9
PH	7.381	7.305	7.321	7.410	7.440
HCO _{3a}	31.1	29.5	24.2	28.1	24.9

hypopneas, snoring with several episodes of prolonged hypopneas. Putting the patient on CPAP at a pressure of 6 cm resulted in abolition of snoring, improved flow and increase in the O₂ saturation. However, episodes of hypopneas persisted which showed a marked improvement on starting BiPAP support at a pressure of 18/8 with further improvement of oxygen saturation.

The PSG was repeated on 10.07.2004 (Fig 5)after two weeks of initiation of medical therapy , the SPO₂ on BiPAP during Phase II sleep had improved to 92% on room air. ACET was withdrawn after ten days and MPA was discontinued after one month.

Patient was discharged with a final diagnosis of morbid obesity with OSA with OHS with hypertension with bronchial asthma with hypothyroidism with advice to continue regular medication and over night BiPAP at pressures of 19/10. Patient at discharge had lost 24 Kg

**Fig 1:** Histogram showing effect of CPAP & BiPAP on sleep stages and oxygen saturation

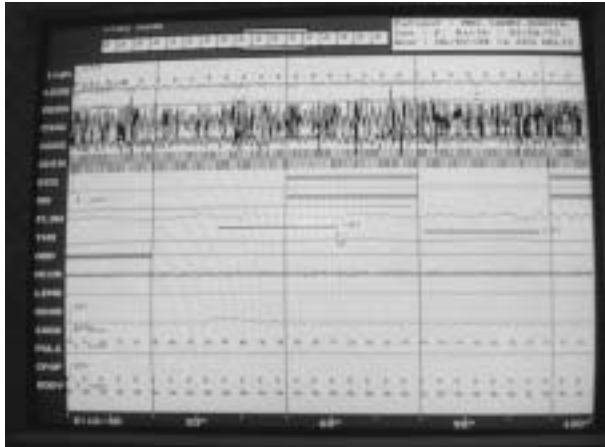


Fig 2 : PSG showing repeated apneas)

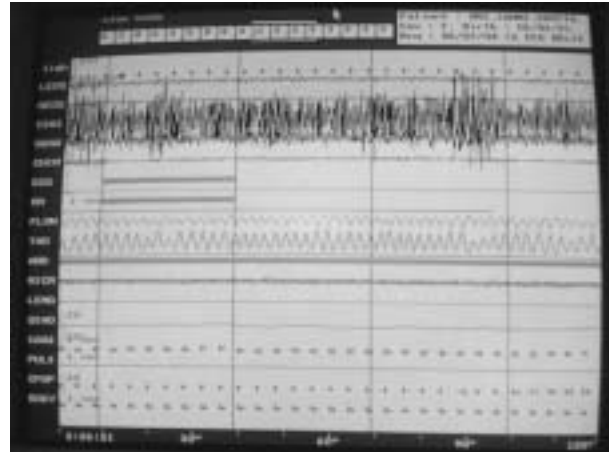

Fig 4: PSG -patient on BiPAP no snoring, no hypopneas, no apneas

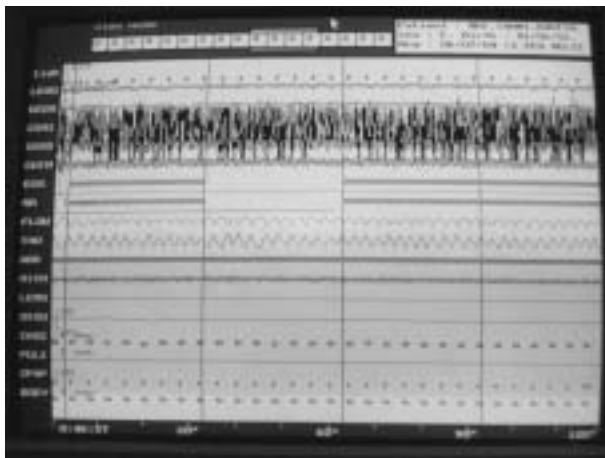


Fig3: PSG - patient on CPAP sleep stage II, no snoring, no apneas, improved saturation, hypopneas persist

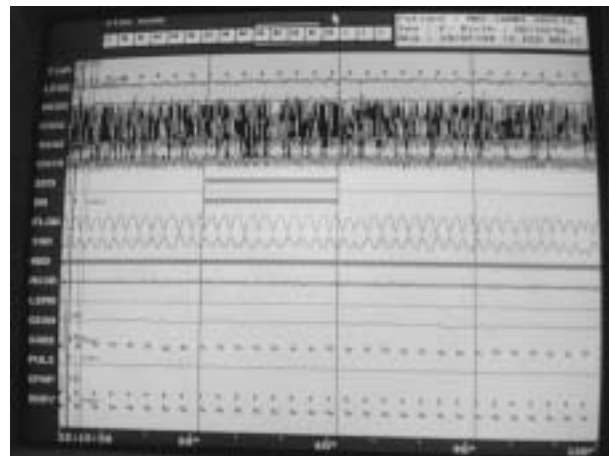


Fig 5: PSG on BiPAP after two weeks of medical therapy & NIV, saturation 92% on room air

(120 Kg) and BMI had decreased from 53 to 46 Kg/Ht².

Discussion

The case presented is remarkable for the fact that the patient with multitude of medical problems along with sleep disordered breathing remained undiagnosed for many years, progressing finally to acute respiratory failure requiring invasive mechanical ventilation. This case also substantiates the role of MPA & ACET with non invasive ventilation in the management of OHS in selected cases.

The patient described was morbidly obese (BMI :

53 on admission). It has been reported that as body mass increased the prevalence of obesity associated hypoventilation also increased significantly. When the body mass index was > 50 Kg/m², hypoventilation was found in 48% obese subjects (7). The proportion of patients with OHS in whom OSAS is present may range between 73.8 (8) and 88.5 (9) an association noted in our case.

Kesler et al (9) have stated that psychological factors related to morbid obesity may predispose patients to underestimate or even be unaware of their disease for a long time.

Another feature noted in our patient as in many other obese patients is the effect of posture on oxygenation. This ventilation perfusion disturbance is the most striking

abnormality of gas exchange found in extreme obesity (10). It is manifested by various degrees of hypoxia but normal arterial carbon dioxide values. The decrease in arterial oxygen tension is usually magnified when the obese subject lies flat, presumably as a result of shallower breathing and further compression of the lungs (basal atelectasis). Also, abdominal fat impedes, the mechanical movement of the chest wall in the supine position (11).

Our patient reported to the emergency in extremis and had to be intubated and ventilated. MacGregor et al and Miller et al(12,13) also suggested that in patients with evidence of impending respiratory failure (such as an uncompensated respiratory acidosis, significant hypoxia, or mental status changes) immediate hospitalization is indicated and require ventilatory support.

Weight loss of at least 10Kg results in significant improvement in vital capacity and maximal voluntary ventilation and a significant reduction in day time PaCO₂ (14). Although data is limited, weight loss has also been shown to significantly increase central ventilatory drive as measured by the diaphragmatic electromyogram response to carbon dioxide inhalation (14). However optimal amount of weight loss has not been studied and long-term outcome of sustained weight loss is not known (15,16). Our patient lost 24 Kg weight during stay in the hospital and therefore improvement may partially be attributed to the effect of loss of weight. Patients who require ventilation for respiratory failure are usually noted to loose significant weight due to loss of accumulated edema fluid.

A subset of obese patients (sleep hypoventilation syndrome)(17)with concurrent obstructive sleep apnea & hypopnea syndrome do not respond to nasal CPAP and require non invasive mechanical ventilation to alleviate daytime hypercapnia. NIV is given by nasal mask either a bi level positive airway pressure device or volume ventilator. Noninvasive ventilatory support in hypoventilation syndrome augments ventilation (17) and is the main stay of treatment. This has been substantiated by other studies (18,19,20). NIPPV can effectively unload the inspiratory muscles in severely obese patients with increased impedance of the respiratory system (21).

The slow response seen in our patient has been noted by other workers. Luis et al (21) have noted in their study that some patients did not totally correct their blood gas values during the hospital admission and many maintained a certain level of hypercapnia at hospital

discharge. Also that PIP levels of > 20 cm H₂O were poorly tolerated. Many patients also required oxygen supplementation initially to maintain adequate oxygen saturation. However, by the first month of treatment most patients had resolution of the respiratory failure. They therefore suggest that it is not necessary to achieve a total correction of the diurnal blood gas within the early weeks of treatment (21).

Treatment for obesity associated hypoventilation syndrome was essential as it was seen in a study in hospitalized patients by Sogol Nowbar et al (7) that at 18 months mortality was 23% among patients of OHS compared to 9% in patients with simple obesity.

Treatment of sleep disordered breathing usually fits into one or more of the five categories; weight loss, pharyngeal surgery, mandibular retention devices, nasal CPAP or pharmacological agents. Of the above drug therapy is the most patient friendly and easy to administer. MPA is the pharmacological agent used most commonly for sleep disordered breathing as a ventilatory stimulant. It is reasoned that MPA increased central responsiveness to CO₂ or hypoxia interrupting the apnea cycle because of inhibition of hypoventilatory portion of the apnoeic cycle. In addition it is proposed that pharyngeal patency is improved with increased drive to the pharyngeal muscles (22,23). Six studies have been conducted with MPA to evaluate its role in sleep disordered breathing (24,25,26,27,28,29). From the data available MPA has not been shown to be very useful in OSA except in hypercapnic patients where the low hypercapnic ventilatory drive stimulated by MPA leads to improvement. This is the possible reason for improvement in our patient where its use supplemented the role of other modalities. However, unlike Sutton et al (30) where MPA was used as the sole therapeutic measure showed sustained improvement of hypercapnia & hypoxia throughout the period of drug therapy and on withdrawal of therapy there was a return of the values to the pre therapeutic levels; the possible explanation for sustained improvement in our case is the concurrent use of NIV with the use of pharmacological agents.

ACET may be useful in cases of sleep disordered breathing because the metabolic acidosis produced by ACET stimulates ventilation. Groups of patients with central, obstructive and mixed sleep apnea have been studied. Studies where ventilatory control were assessed by White and colleagues (31) and De Backer and colleagues (32) showed a significant improvement in

patients with central sleep apnea during treatment with ACET. Sleep stage distribution was not altered by ACET. Possibly, ACET lowers the apnoeic threshold for CO₂ as might be expected with a shift of the hypercapnic ventilatory response slope to a lower CO₂ level. Thus, ventilation is stimulated with minimal hypercapnia thereby preventing the central apnea from occurring (33).

In conclusion, the case presented above had a multitude of medical problems. However morbid obesity was the cause as well as the effect of her sleep disordered breathing. Her sleep disordered breathing remained undiagnosed and untreated for many years ultimately requiring the patient to be put on invasive mechanical ventilation followed by NIV to correct the sleep disordered breathing. Another very interesting feature of this case was the role of MPA and ACET in the correction of hypercarbia suggesting that MPA and / or ACET can be useful in some difficult cases of sleep disordered breathing.

It is probable that other regulatory measures like the gradual resetting of the respiratory centre control and renal compensatory mechanisms could play a role in correction of SDB in such patients. However, validation of these theories would require a controlled trial.

Our case also substantiates the view of Nowbar S. et al (34) who showed in a recent study that although health care providers were informed of the obesity associated hypoventilation, only 13% of patients were discharged with therapies known to be effective. Further early diagnosis and initiation of appropriate therapy has been shown to significantly reduce patient fees and hospital admissions (35).

Authors' affiliations

Dr. J. C. Suri, Head of the Department
 Dr D. Bhattacharya, Senior Chest Physician
 Dr M. K. Sen, Senior Chest Physician
 Dr. S. Chakrabarti, Senior Chest Physician
 Department of Pulmonary, Critical Care & Sleep Medicine,
 Vardhaman Mahavir Medical College & Safdarjang Hospital,
 New Delhi

References

1. Achincloss JH, Cook E, Renzetti AD. Clinical and physiological aspects of a case of polycythemia and alveolar hypoventilation. *J Clin Invest* 1955; 34: 1537-45.
2. Bedell GN, Wilson WR, Seebom PM: Pulmonary function in obese persons. *J Clin Invest* 37: 1049-1060, 1958
3. Alexander JK, Amad KH, Cole Vw: Observations on some clinical features of extreme obesity with particular reference to cardiorespiratory effect. *Am J Med* 32:512-524, 1962(13-12)
4. Sampson MG, Grassino A: Neurochemical properties in obese patients during carbon dioxide rebreathing *Am J Med* 75:81,1983(14-57)
5. Zwillich CW, Sutton FD, Pierson DI, et al: Decreased hypoxic ventilatory drive in the obesity-hypoventilation syndrome. *Am J Med* 59:343, 1975(14-71)
6. Flemmons WW, Whitelaw WA, Brant R, Remmers JE, Likelihood ratios for a sleep apnea clinical prediction rule. *Am J Respir Crit Care Med* 1994;150:1279-85.
7. Sogol Nowbar, MD, Kristin M. Burkart, MD, Ralph Gonzales, MD, Andrew Fedorowicz, MD, Wendolyn S. Gozansky, MD, MPH, Jon C. Gaudio, MD, Matthew R.G. Taylor, MD, Clifford W. Zwillich, Obesity-Associated Hypoventilation in Hospitalized Patients: Prevalence, Effects, and Outcome - MD - *Am J Med.* 2004; 116:1-7'
8. Sugerman HJ, Fairman RP, Sood RK, et al. Long-term effects of gastric surgery for treating respiratory insufficiency of obesity. *Am J Clin Nutr* 1992; 55(2):597S-601S'
9. Kessler R, Chaouat A, Schinkewitch P, et al. The obesity-hypoventilation syndrome revisited. A prospective study of 34 consecutive cases. *Chest* 2001; 120:369-76'.
10. Barrera, I, Hillyer, P, Aneanio, G & Hechtel, J (1973): The distribution of ventilation, diffusion and blood flow in obese patients with normal and abnormal blood gases. *Am Rev Respir Dis* 108, 819-830'
11. Bedell G.N. Wilson W.R & Seebom. P.M.(1958): Pulmonary function in obese patients *J Clin Invest* 37, 1049-1060'
12. Mac Gregor MI, Block AJ, Ball WC Serious complications and sudden death in the Pickwickian Syndrome. *Hopkins Med J.* 1970: 126:279-295'
13. Miller A, Granada M. In-hospital mortality in the Pickwickian syndrome. *Am J Med.* 1974; 56:144-150'
14. Rochester DF, Enson Y. Current concepts in the pathogenesis of the obesity-hypoventilation syndrome. *Am J Med.* 1974;57:402-420'
15. Rochester D. Obesity and pulmonary function. In: Alpert MA, Alexander JK, editors. *The heart and lung in obesity.* Armonk, Ny: Futura Publishing Company. Inc; 1998. p.109-131'
16. Koenig SM, Suratt PM. Obesity and sleep-disordered breathing. In: Alpert MA, Alexander JK, editors. *The heart and lung in obesity.* Armonk, NY: Futura Publishing company, Inc; 1998. p.248-279'
17. The report of an American Academy of Sleep Task Force. Sleep related breathing disorders in adults: Recommendations for syndrome definition and measurement techniques in clinical research. *Sleep.* 1999;22:667-635.
18. Piper AJ, Sullivan CE. Effects of short term NIPPV in the treatment of patients with severe obstructive sleep apnea and hypercapnia. *Chest* 1994; 105:434-440.

19. **Waldhorn RE.** Nocturnal nasal intermittent positive pressure ventilation with bi-level positive airway pressure (BiPAP) in respiratory failure. *Chest* 1992; 101:516-521'
20. **Schafer H,** Ewig S, Hasper E, et al. Failure of CPAP therapy in obstructive sleep apnoea syndrome: predictive factors and treatment with bilevel-positive airway pressure. *Respir Med* 1998; 92:208-215'
21. **Pankow W,** Hljesh N, Schuttler F, et al. Influence of noninvasive positive pressure ventilation on inspiratory muscle activity in obese subjects. *Eur Respir J* 1997; 10:2847-2852'
22. **Luis a. Perez de Llano,** MD; Rafael Golpe, MD; Montserrat Ortiz Piquer, MD; Alejandro Veres Racamonde, MD; Manuel Vazquez Caruncho, MD; Olga Caballero Muinelos, RN; and Cristina Alvarez Carro, RN 'Short term and Long term effects of nasal intermittent positive pressure ventilation in patients with obesity – Hypoventilation syndrome'. *CHEST* 2005; 128:587-594.
23. **Skatrud, J.B.**J.A.Dempsey, and D.J.Kaiser,. Ventilatory response to medroxyprogesterone acetate in normal subjects; time course and mechanism *J.Appl. Physiol.* 1978; 44:939-944'
24. **Zwillich, C.W.M.R.** Natalino, F.D., Sutton and J.V. Weil. Effects of progesterone on chemosensitivity in normal men. *J.Lab. Clin. Med.* 1978;92:262-269'.
25. **Strohl, K.P,** N.J.Hensley, N.A.Saunders, S.M.Scharf, R.Brown, and R.H.Ingram. Progesterone administration and progressive sleep apnea *J.A.M.A.* 1981;245:1230-1232';
26. **Block, A.J.,** J.M.Wyme, P.G.Boysen, S.Lindsey, c.Martin, and B.Cantor,. Menopausd medroxyprogesterone and breathing during sleep. *Am J.Med.* 1981;70:506-510;
27. **Rajagopal, K.R.,** PH.Abbrecht, and B.Jabbari.. Effects of medroxyprogesterone acetate in obstructive sleep apnea. *Chest* 1986;90:815-821.
28. **Cook, W.R.,** J.J.Benich and S.A.Wooten. Indies of severity of obstructive sleep apnea syndrome do not change during medroxyprogesterone acetate therapy. *Chest* 1989;96:262-266;
29. **Kimura, H.,** D.Tatsumi, F.Kunitomo.S.Okita, H.Tojima, S.Kouchiyama, S.Masuyama, T.shinozaki, Y.Honda and T.Kuriyama. Progesterone therapy for sleep apnea syndrome evaluated by occlusion pressure response to exogenous loading. *Am. rev. Respir. Dis.* 1989; 139:1198-1206;
30. **Cistulli, PA,** D.J.Barnes, R.R.Grunstein, and C.E.,sullivan.. Effect of short term hormone replacement in the treatment of obstructive sleep apnoea in postmenopausal women. *Thorax* 1994;49:699-702'
31. **Frank D.Sutton. Jr.** M.D.Clifford W.zwillich, M.D., C.Edward Creagh, M.D., David. J.Pierson, M.D. and John V.Weil, M.D., Denver, Colorade'. Progesterone for Outpatient Treatment of Pickwickian Syndrome. *Annals of Internal Medicine* 1975;83:476-479,
32. **White, D.P.,** C.W.Zwillich, C.K.Picket, N.J.Douglas, J.J.Findley, And J.V.Weil.. Central sleep apnea.Improvement with acetazolamide therapy. *Arch. Intern. Med.* 1982;142; 1816-1819
33. **DeBacker, W.A.,** J.Verbraecken, M.Willemen. W.Wittesaele, W.DeCook. and PVan deHeyning.. Central apnea index decrease after prolonged treatment with acetazolamide. *Am.J.Respir, Crit. Care Med.* 1995; 151:87-91
34. **David W. Hudge,** and Sitthep Thanakitcharu. Pharmacologic Treatment of Sleep-disordered Breathing' *Am J Respir Crit Care Med.* 1998; 158: 691-699.
35. **Nowbar S,** Burkhart KM, Gonzales R, et al. Obesity associated hypoventilation in hospitalized patients: prevalence, impact, and outcome. *Am J.Med.*2004; 116:1-7.
36. **Berg G,** Delaiye K, Manfreda J, et al. The use of health-care resources in obesity hypoventilation syndrome. *Chest.* 2001;120: 377-383.